

Taeniasis: An Unusual Presentation

SHOBHA PRASADA¹, SEVITHA BHAT², K VIDYALAKSHMI³

ABSTRACT

We report a case of 45-year-old male presenting with the history of nasal expulsion of segments of *Taenia saginata*. This route of expulsion is a rare occurrence. The report stresses this unusual presentation of taeniasis in endemic region.

Keywords: Gastrointestinal, Ova, Parasite, Proglottid

CASE REPORT

A 45-year-old male, watchman by occupation, presented to us with a chief complaint of segments coming out from a nostril. The segment was motile when it came out from the nostril. There was also a history of passing multiple segments in stool for a month. Patient had history of recurrent parasitic infestations since eight years, for which he was treated multiple times. He was admitted to another hospital four years ago. Patient was unable to provide details of that admission. Patient consumed chicken and however, could not recollect eating beef and pork. He gave a history of eating wild rabbit meat eight years before. There is no previous history of similar episodes of passing segments from nostril, respiratory symptoms, parasitic infestation in family members, seizures, and ophthalmic symptoms. He gave history of weight loss around 10 kg since five years. There were no other comorbidities.

On general and systemic evaluation, the patient was poorly built with no other significant clinical findings. Patient was advised admission for further evaluation and management. However, patient was not willing for the same. Patient underwent outpatient department based investigations which showed: Hb-12.4 gm%; total leukocyte count of 11,800 cells/mm³, differential leucocyte count showed 23% of eosinophils. Peripheral smear was suggestive of normocytic normochromic anaemia. Chest X-ray and ultrasonography of abdomen did not show any abnormality.


The segments expressed from nose and stool sample was sent for parasitological evaluation. Segment received [Table/Fig-1] was processed in the lab by injecting the India ink into it by locating the main branch of uterus of worm segment. It was examined with a hand lens after pressing between two slides.

The number of lateral branches was counted. Segment received had around 18 branches. The microscopic examination of wet mount of stool showed the presence of typical *Taenia* eggs too [Table/Fig-2]. Both the segments expressed from nose and from stool showed similar characteristics. Both the segments were actively motile and based on the uterine branching; it was identified as *Taenia saginata*.

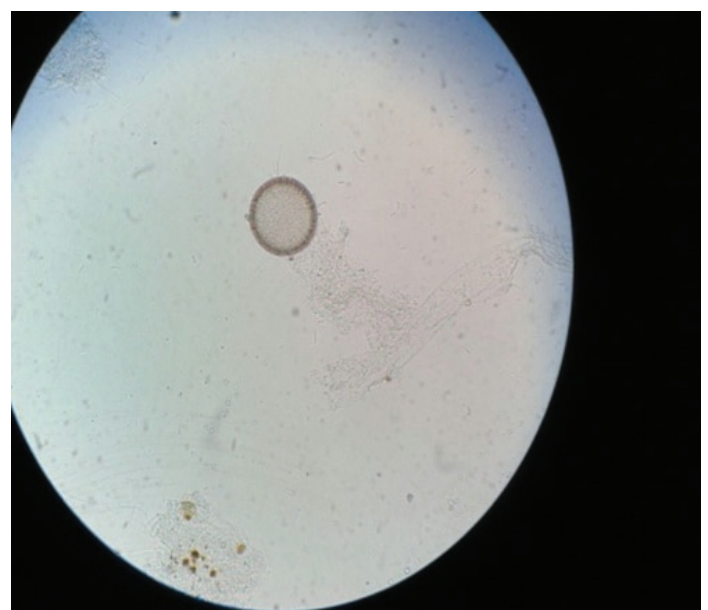
The patient was treated with Tab Albendazole. The patient was advised to improve personal hygiene and to avoid eating undercooked beef and to maintain clean personal habits.

DISCUSSION

Taenia spp. are common parasites of humans. The two important species include the pork tapeworm or *T. solium* and the beef tapeworm or *T. saginata*. *Taenia* sp. found in Asia is a subspecies



[Table/Fig-1]: Proglottid of *T. saginata*.



[Table/Fig-2]: Microscopic view of *Taenia* egg in wet mount preparation of stool at 40X.

of *T. saginata* and it has been renamed as *T. saginata asiatica*. Taeniasis is endemic in Southeast Asia [1].

Taenia saginata causes intestinal taeniasis, manifesting as abdominal discomfort, nausea, vomiting and weight loss. Some patients complain of passage of proglottids in the stool. Adult parasite may rarely be present in the stomach and the gastric secretions, vomitus may harbour the parasite. This can lead to oral transmission of infection among caretakers [2].

Taenia saginata, commonly called as beef tapeworm is worldwide in distribution. Infection is found in those who eat beef. Human acquires infection by ingesting raw or uncooked beef containing cysticerci (larval form). Cysticerci develop into adult worms in the upper part of the small intestine. Eggs, proglottids of the parasite may be demonstrated in the faeces [3].

Cysticercus attaches to the wall of the small intestine by means of scoleces and becomes a mature tapeworm. But there have been reports of migration of the parasite causing complications [4,5]. Similar case of nasal expulsion in an 18-year-old girl was reported by Sheikh M et al., nasal expulsion of *Taenia saginata* could be due to reverse peristalsis. Intestinal taeniasis manifests as abdominal discomfort, indigestion, nausea, diarrhoea, and weight loss [6]. The complications include intestinal obstruction, obstruction of bile ducts or pancreatic duct, leading to cholecystitis, acute pancreatitis and granulomatous gastritis [7-9]. Diagnosis of intestinal taeniasis rests on demonstration of the typical *Taenia* eggs in the stool. Species identification is done by examining the proglottids. Differentiation of the two human *Taenia* species is based on the number of lateral uterine branches present in gravid proglottids and the motility of the proglottid. *Taenia saginata* have 15-20 and *T. solium* have 7-13 lateral branches. Treatment of taeniasis includes oral medicine such as praziquantel or niclosamide. Personal hygiene and eating cooked beef or meat are usually recommended to avoid further complications in treatment of taeniasis.

CONCLUSION

To the best of our knowledge from this region of coastal Karnataka, this is the first case of nasal expulsion of *Taenia saginata*. Eating uncooked beef or pork can lead to such complications. Maintenance of hygiene while preparing food is must. Eggs of *Taenia* can also spread from the hands of the cook. It is recommended to have proper personal and cooking hygiene while handling such foods. Early diagnosis and treatment of taeniasis will help in prevention of any further complications.

ACKNOWLEDGEMENTS

The authors are grateful to Manipal University for all the support.

REFERENCES

- [1] Fan PC, Lin CY, Chen CC, Chung WC. Morphological description of *Taenia saginata asiatica* (Cyclophyllidae: Taeniidae) from man in Asia. *J Helminthol*. 1995;69:299-303.
- [2] Uygur-Bayramiçi O, Yavuzer D, Dolapçioğlu C, Senu S, Tuncer K. Granulomatous gastritis due to taeniasis. *J Clin Gastroenterol*. 1998;27(4):351-52.
- [3] Galán-Puchades MT, Fuentes MV. Lights and shadows of the *Taenia asiatica* life cycle and pathogenicity. *Trop Parasitol*. 2013;3(2):114-19.
- [4] Mafojane NA, Appleton CC, Kreczek RC, Michael LM, Willingham AL. The current status of neurocysticercosis in Eastern and Southern Africa. *Acta Trop*. 2003;87:25-33.
- [5] Liu YM, Bair MJ, Chang WH, Lin SC, Chan YJ. Acute pancreatitis caused by tapeworm in the biliary tract. *Am J Trop Med Hyg* 2005;73:377-80.
- [6] Sheikh M, Sheikh I, Ali I, Reshi F. Nasal expulsion of *Taenia saginata*: a rare route of expulsion. *Internet J Surg*. 2007;16(2).
- [7] Malik AA, Wani RA, Bari S. Acute acalculous cholecystitis due to *Taenia saginata*. *Ann Saudi Med*. 2008;28(5):388-89.
- [8] Ahsan S, Zia SA, Ahmed J. A case of *Taenia saginata* (tapeworm) infestation of the uterus presenting with abnormal vaginal bleeding. *J Pak Med Assoc*. 2006;56:377-78.
- [9] Karanikas ID, Sakellaridis TE, Alexiou CP, Siaperas PA, Fotopoulos AC, Antsaklis GI, et al. *Taenia saginata*: a rare cause of bowel obstruction. *Trans R Soc Trop Med Hyg*. 2007;101:527-28.

PARTICULARS OF CONTRIBUTORS:

1. Student, Department of Microbiology, Kasturba Medical College, Mangalore, Karnataka, India.
2. Associate Professor, Department of Microbiology, Kasturba Medical College, Mangalore, Karnataka, India.
3. Professor and Head, Department of Microbiology, Kasturba Medical College, Mangalore, Karnataka, India.

NAME, ADDRESS, E-MAIL ID OF THE CORRESPONDING AUTHOR:

Dr. Sevitha Bhat,
Associate Professor, Department of Microbiology, Kasturba Medical College, Mangalore, Karnataka, India.
E-mail: sevitha@rediffmail.com

Date of Submission: **Dec 03, 2016**

Date of Peer Review: **Jan 06, 2017**

Date of Acceptance: **Apr 20, 2017**

Date of Publishing: **Jun 01, 2017**

FINANCIAL OR OTHER COMPETING INTERESTS: None.